

Renal anaplastic mesenchymal tumor. A rare variant of Wilms' tumor?

Department of Urology, Martha Maria Medical Center, Nuremberg, Germany

Apostolos P. Labanaris, Sven Scheuring, Reinhold Nützel, Reinhard Kühn

Background

Wilms' tumor can appear with a wide spectrum of morphologic features which can sometimes cover or delay the recognition of other clinicopathologic entities of the kidney. We present a case of a new tumor entity of the kidney.

Case Report

In March 2006, a young female patient presented to our department complaining of right flank pain the last two weeks. Weight loss and fatigue were also observed. Physical examination revealed a palpable, smooth abdominal mass. Ultrasound revealed a heterogeneous mass within the right kidney, with a solid lesion and a central area of increase reflectivity and in some parts with an ecogenicity similar to that of the renal parenchyma measuring about 22cm x 12cm. MRI confirmed the findings and additionally raised no suspicion for lymph node involvement, extrarenal tumor extension into the perirenal fat or adjacent structures, vena cava involvement or lung metastasis. The preoperative diagnosis made was that of RCC or Wilms' tumor. Radical nephrectomy with regional lymphadenectomy was performed. A complete resection with negative surgical margins was achieved and no significant intraoperative complications were noted.

Histopathologic Features

At first, a histopathological diagnosis of an unusual anaplastic Wilms' tumor, Stage II was made. Because of its unusual nature, a further histopathological examination was performed.

The histologic features exhibited:

- Small primitive mesenchymal cells coexisting with a spindle cell component.
- Anaplastic nuclear changes with bizarre pleomorphic multinucleated cells containing enlarged irregular hyperchromatic nuclei which were diffusely scattered throughout the tumor well-formed islands of hyaline cartilage.
- The presence of multiloculated cysts separated by thin fibrous septa and lined by hobnail epithelium.
- Foci of necrosis and single cell necrosis were featured in the solid tumor area.
- There was an absence of larger areas with blastemalike cells, absence of any epithelial differentiation, and also the presence of very atypical and "wildly" anaplastic cells in the stroma and cartilage, features consistent with Wilms tumor.

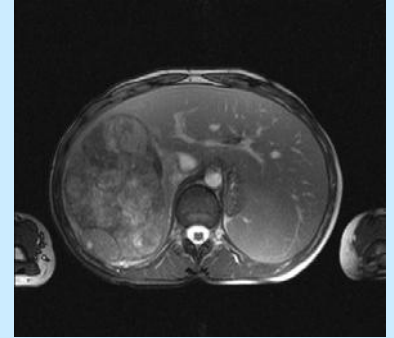
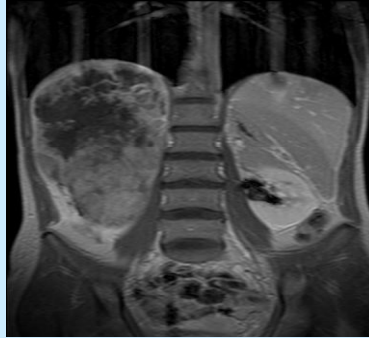The immunohistochemical features exhibited:

- The tumor of being vimentin-positive.
- Immunohistochemical studies with CD-99, p53, S-100, CD56, Desmin and Synaptophysin were negative.

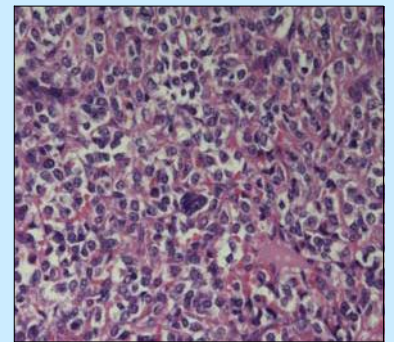
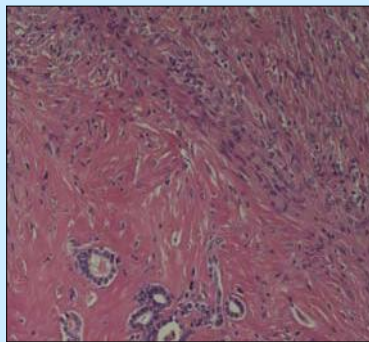
Histopathologic Diagnosis

Renal anaplastic mesenchymal tumor of high malignancy, a tumor not previous described in literature, a new tumor entity.

Radiological Features



Histopathological Features



Discussion

Vujanic et. al¹ in a novel study, by reviewing sections of tumors coded as "unusual" anaplastic Wilms tumors from the National Wilms Tumor Study Pathology Center (NWTSPC), the International Society of Pediatric Oncology (SIOP), and the United Kingdom Children's Cancer Study Group (UKCCSG) trials, resulted in the recognition of a series of 20 cases of a new clinicopathologic entity, the anaplastic sarcoma of the kidney. The histopathology of this tumor exhibited features exactly like the patient described in this report. The patient described in this report was treated as if he had had an anaplastic Wilms' tumor Stage II. The patients described by Vujanic were treated according to the initial diagnosis provided by the institutional pathologists and placed on either the NWTSPC or SIOP protocols for treatment. The overall outcome was reasonably good, with 10/ 13 patients with the median of 8 years of follow-up, surviving their disease. Similarly, our patient is free of diseases and no significant complications have appeared during and after radiochemotherapy.

Conclusions

We have described a renal tumor of high malignancy, namely the renal anaplastic mesenchymal tumor which is not a variant of Wilms' tumor but belongs to a new tumor identity, first described by Vujanic, called the anaplastic sarcoma of the kidney. Although it is evident that newer immunohistochemical staining and molecular probes should be applied to this neoplasm in an attempt to learn more about its origin and pathogenesis, it is sensible to keep treating such patients as if they had anaplastic Wilms tumor, since they seemed to have responded well to this way of treatment.

References:

1. [Vujanic GM, Kelsey A, Periman EJ, Sandstedt B, Beckwith JB](#). Anaplastic sarcoma of the kidney: a clinicopathologic study of 20 cases of a new entity with polyphenotypic features. Am J Surg Pathol. 2007 Oct;31(10):1459-68.